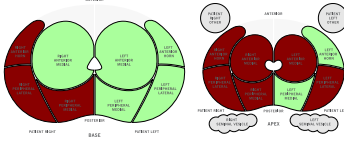




<b>Encounter Information</b> <b>Redacted R. Redacted</b> 81/M DOB:01/01/1943 P:Redacted  <b>BVP-24-00120</b> STAGE/DRE: N/A PSA: 6.9	<b>Physician</b> <b>D. Russell Locke, M.D.</b> Vantage Urologic Institute 9401 SW Highway 200 STE 502 Ocala, FL 34481  P: (352) 861-2115 F: (352) 854-5726 COLLECTED:2024	<b>Laboratory</b> <b>PathNet UT</b> 2889 W Ashton Blvd Suite 300 Lehi, UT 84043  P: 801-770-0027 F: 385-352-7951 RECEIVED:2024	<b>Pathologist</b> <b>Joseph Migliozi, M.D.</b> Vantage Health 9401 SW Highway 200, Ste 502 Ocala, FL 34481  P: 352-861-2296 F: 352-671-2737 E-SIGNED: 03/09/2024 07:29 AM
--	---	---	--

Result Summary	Cores Involved	Gleason Group	Perineural Invasion (PNI)	Extraprostatic Extension (EPE)
<b>Malignant</b>	9 (out of 22) cores	Group II (3+4=7)	None	None

**Prostate Diagram**  


**Photomicrographs**

Site	Microscopic Diagnosis	Gleason	% Pattern 4	% Involvement		Per Core (mm)		
				Length	Area	Capsule → Deep	Max Dim	Gross Length
LEFT ONE BXBOARD	A Left Peripheral Medial Apex	BENIGN PROSTATIC TISSUE						14.6
	B Left Peripheral Medial Base	BENIGN PROSTATIC TISSUE						15.6
	C Left Peripheral Lateral Apex	ADENOCARCINOMA	3+3=6		30%	50%		13.7
	D Left Peripheral Lateral Base	BENIGN PROSTATIC TISSUE						16.9
	E Left Anterior Horn Apex	BENIGN PROSTATIC TISSUE						13.7
	F Left Anterior Horn Base	BENIGN PROSTATIC TISSUE						13.4
RIGHT ONE BXBOARD	G Left Anterior Medial Apex	ADENOCARCINOMA	3+3=6		1%	1%		9.8
	H Left Anterior Medial Base	BENIGN PROSTATIC TISSUE						14.6
	I Right Peripheral Medial Apex	ADENOCARCINOMA	3+4=7	25%	10%	15%		14.6
	J Right Peripheral Medial Base	ADENOCARCINOMA	3+3=6		5%	10%		18.7
	K Right Peripheral Lateral Apex	ADENOCARCINOMA	3+3=6		25%	50%		17.6
	L Right Peripheral Lateral Base	ADENOCARCINOMA	3+3=6		5%	15%		14.5
M Right Anterior Horn Apex	ADENOCARCINOMA	3+4=7	10%	4%	5%		17.7	
N Right Anterior Horn Base	ADENOCARCINOMA	3+3=6		10%	15%		17.7	
C	O Right Anterior Medial Apex	ADENOCARCINOMA	3+3=6		10%	35%		13.7
	P Right Anterior Medial Base	BENIGN PROSTATIC TISSUE						22.2

Grossed on 03/08/2024 at 01:02 PM by Joseph Migliozi, MD

<b>Ancillary Tests</b> The following ancillary tests were ordered: <b>ConfirmMDx, Genomic Prostate Score</b> The results will be reported separately.
---



# Prostate Biopsy Report

REPORT DATE: 2024

PAGE: 2 of 4

9401 SW Highway 200 Ste 502, Ocala FL 34481  
Phone: 352-861-2115 Fax: 352-854-5726  
vantageurology.com

Encounter Information	Physician	Laboratory	Pathologist
<p><b>Redacted R. Redacted</b></p> <p>81/M DOB:01/01/1943 P:Redacted</p> <p><b>BVP-24-00120</b></p> <p>STAGE/DRE: N/A PSA: 6.9</p>	<p><b>D. Russell Locke, M.D.</b></p> <p>Vantage Urologic Institute 9401 SW Highway 200 STE 502 Ocala, FL 34481</p> <p>P: (352) 861-2115 F: (352) 854-5726 COLLECTED:2024</p>	<p><b>PathNet UT</b></p> <p>2889 W Ashton Blvd Suite 300 Lehi, UT 84043</p> <p>P: 801-770-0027 F: 385-352-7951 RECEIVED:2024</p>	<p><b>Joseph Migliozi, M.D.</b></p> <p>Vantage Health 9401 SW Highway 200, Ste 502 Ocala, FL 34481</p> <p>P: 352-861-2296 F: 352-671-2737 E-SIGNED: 03/09/2024 07:29 AM</p>

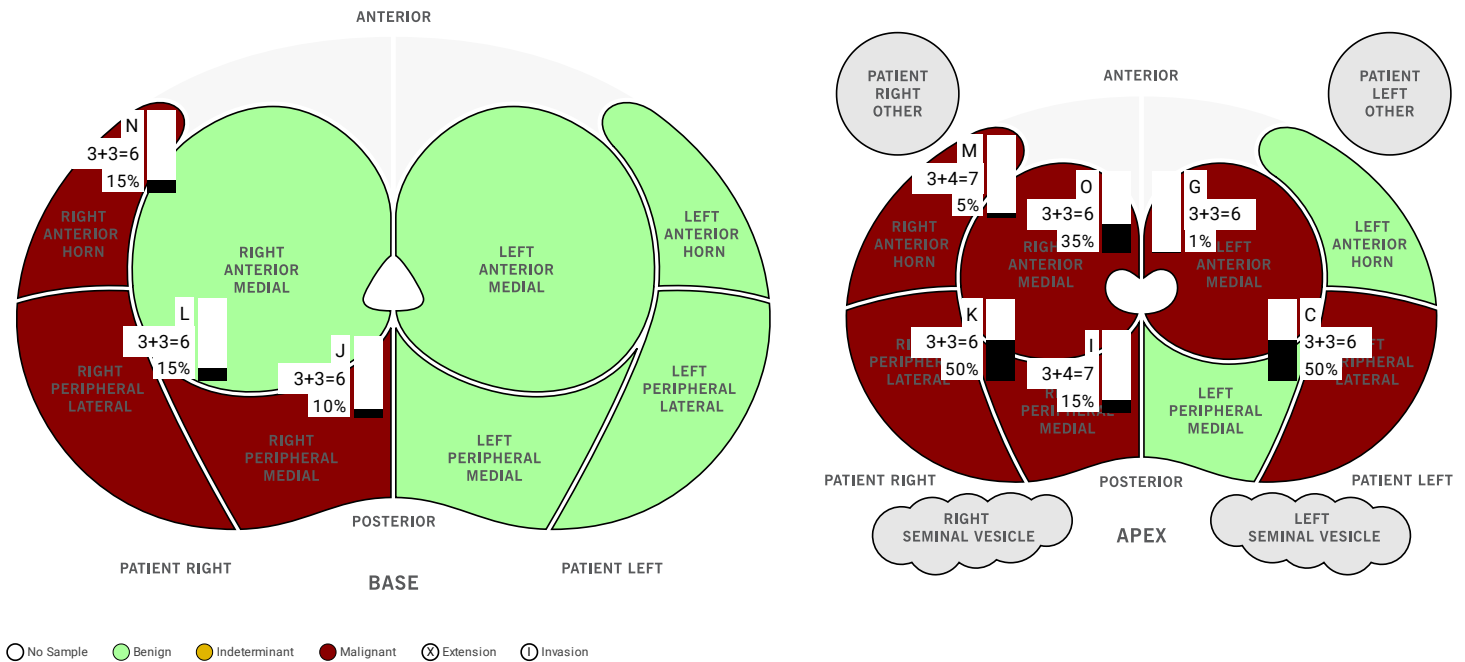
ICD-10 Codes	CPT Codes
N40.1, R97.20, C61	Vantage Health: G0416 x1;

This laboratory is certified under CLIA to perform high-complexity clinical lab testing. Many well-established testing procedures, such as IHC-staining and WSI for digital interpretation, have not been cleared or approved by the US Food and Drug Administration. The FDA does not regulate the practice of laboratory medicine. The tests reported herein were developed for clinical, non-investigational purposes, and have been validated for safety by the Medical Director, using well-accepted performance criteria, in accordance with CLIA standards. All IHC tests were performed using appropriate control slides. Controls were found to be acceptable unless otherwise noted. WSI and the digital platform have been extensively validated as a Laboratory Developed Test (LDT). The slide production facility is located at 2889 W. Ashton Blvd. Suite 300, Lehi, UT 84043. All extant materials for this case are retained at the slide production facility. CLIA# 10D1087213 CAP# 7214934

<b>Encounter Information</b> <b>Redacted R. Redacted</b> 81/M DOB:01/01/1943 P:Redacted <b>BVP-24-00120</b> STAGE/DRE: N/A PSA: 6.9	<b>Physician</b> <b>D. Russell Locke, M.D.</b> Vantage Urologic Institute 9401 SW Highway 200 STE 502 Ocala, FL 34481 P: (352) 861-2115 F: (352) 854-5726 COLLECTED:2024	<b>Laboratory</b> <b>PathNet UT</b> 2889 W Ashton Blvd Suite 300 Lehi, UT 84043 P: 801-770-0027 F: 385-352-7951 RECEIVED:2024	<b>Pathologist</b> <b>Joseph Migliozi, M.D.</b> Vantage Health 9401 SW Highway 200, Ste 502 Ocala, FL 34481 P: 352-861-2296 F: 352-671-2737 E-SIGNED: 03/09/2024 07:29 AM
--	---	---	--

Result Summary	Cores Involved	Gleason Group	Perineural Invasion (PNI)	Extraprostatic Extension (EPE)
<b>Malignant</b>	9 (out of 22) cores	Group II (3+4=7)	None	None

## Prostate Diagram:



Site	Microscopic Diagnosis	Gleason	% Pattern 4	Per Sample		Per Core (mm)			
				% Involvement Length	% Involvement Area	Capsule → Deep	Max Dim	Gross Length	
L	C Left Peripheral Lateral Apex	ADENOCARCINOMA	3+3=6	30%	50%		2.4	13.7	
	G Left Anterior Medial Apex	ADENOCARCINOMA	3+3=6	1%	1%		0.3	9.8	
C	I Right Peripheral Medial Apex	ADENOCARCINOMA	3+4=7	25%	10%	15%		1.5	14.6
	J Right Peripheral Medial Base	ADENOCARCINOMA	3+3=6	5%	10%		0.9	18.7	
	K Right Peripheral Lateral Apex	ADENOCARCINOMA	3+3=6	25%	50%		4.3	17.6	
	L Right Peripheral Lateral Base	ADENOCARCINOMA	3+3=6	5%	15%		1.0	14.5	
	M Right Anterior Horn Apex	ADENOCARCINOMA	3+4=7	10%	4%	5%		0.7	17.7
	N Right Anterior Horn Base	ADENOCARCINOMA	3+3=6	10%	15%		6.1	17.7	

<p><b>Encounter Information</b></p> <p><b>Redacted R. Redacted</b></p> <p>81/M DOB:01/01/1943 P:Redacted</p> <p><b>BVP-24-00120</b></p> <p>STAGE/DRE: N/A PSA: 6.9</p>	<p><b>Physician</b></p> <p><b>D. Russell Locke, M.D.</b></p> <p>Vantage Urologic Institute 9401SW Highway 200 STE 502 Ocala, FL 34481</p> <p>P: (352) 861-2115 F: (352) 854-5726 COLLECTED:2024</p>	<p><b>Laboratory</b></p> <p><b>PathNet UT</b></p> <p>2889 W Ashton Blvd Suite 300 Lehi, UT 84043</p> <p>P: 801-770-0027 F: 385-352-7951 RECEIVED:2024</p>	<p><b>Pathologist</b></p> <p><b>Joseph Migliozi, M.D.</b></p> <p>Vantage Health 9401 SW Highway 200, Ste 502 Ocala, FL 34481</p> <p>P: 352-861-2296 F: 352-671-2737 E-SIGNED: 03/09/2024 07:29 AM</p>
--	---	---	---

Site	Per Sample				Per Core (mm)			
	Microscopic Diagnosis	Gleason	% Pattern 4	% Involvement Length Area		Capsule → Deep	Max Dim	Gross Length
O Right Anterior Medial Apex	ADENOCARCINOMA	3+3=6		10%	35%		3.6	13.7
							3.6	16.9
							3.6	15.9
							3.6	16.6

Grossed on 03/08/2024 at 01:02 PM by Joseph Migliozi, MD